

## The Role of Ultrasonography in the Management of Lung and Pleural Diseases

**C. Martin Rumende**

Department of Internal Medicine, Faculty of Medicine, University of Indonesia – Cipto Mangunkusumo Hospital. Jl. Diponegoro no. 71, Jakarta Pusat 10430, Indonesia. Correspondence mail: divisipulmonologi@yahoo.co.id.

### ABSTRAK

*Pemeriksaan ultrasonografi di bidang pulmonologi memberikan kemajuan yang revolusioner karena sangat membantu dalam upaya diagnosis dan tatalaksana berbagai kelainan pleura dan paru yang letaknya perifer. Pemeriksaan ultrasonografi paru memungkinkan klinisi untuk mendiagnosis beberapa kelainan paru secara lebih cepat misalnya dalam mendiagnosis adanya efusi pleura. Pemeriksaan ultrasonografi juga sangat membantu klinisi dalam melakukan beberapa tindakan invasif di bidang pulmonologi sehingga dapat meningkatkan keberhasilan dan mengurangi kemungkinan komplikasi. Selain efusi pleura kelainan paru lain yang dapat didiagnosis dengan USG misalnya tumor paru yang letaknya perifer dan kelainan pleura lain akibat fibrosis pleura dan tumor pleura metastasis maupun tumor pleura primer (mesothelioma). Tindakan-tindakan invasif yang dapat dilakukan dengan tuntunan USG adalah aspirasi efusi yang jumlahnya minimal, Transthoracic Needle Aspiration, Transthoracic Biopsies dan insersi chest tube. Pemeriksaan ultrasonografi paru juga mempunyai beberapa keuntungan lain yaitu bebas dari bahaya radiasi, portable, bersifat non-invasif dan biaya pemeriksaannya relatif murah. Pemeriksaan USG toraks juga mempunyai keterbatasan khususnya untuk mendeteksi kelainan yang terdapat di mediastinum.*

**Kata kunci:** ultrasonografi, transducer, pemeriksaan paru, penyakit paru.

### ABSTRACT

*Ultrasonographic examination in pulmonology provides a revolutionary advance because it is very helpful in the diagnosis and management of various pleural and peripheral pulmonary defects. Lung ultrasonography allows the clinicians to diagnose some pulmonary abnormalities more rapidly, including the diagnosis of pleural effusion. Ultrasound examination also provides great assistance for the clinicians to perform invasive techniques in the field of pulmonology, which may increase the success rate and reduce the likelihood of complications. In addition to pleural effusion, other lung disorders can be diagnosed by ultrasound such as peripheral lung tumors and other pleural abnormalities caused by pleural fibrosis and tumor metastasis as well as the primary pleural tumor (mesothelioma). Ultrasound-guided invasive procedures include aspiration of minimal effusion, Transthoracic Needle Aspiration, Transthoracic biopsies and chest tube insertion. Lung ultrasound also offers other advantages, i.e. free from radiation hazards, portable, non-invasive and relatively inexpensive. Ultrasonography in the thorax also has its limitations, especially in detecting mediastinal abnormalities.*

**Key words:** ultrasonography, transducer, lung examination, pleural disease.

## INTRODUCTION

Ultrasonography is very useful in lung and pleura radiography due to its real-time response characteristics and multiplanar imaging capability. Moreover, because of its portability, ultrasound is very important for examining patients at emergency unit and ICU.

Another advantage of ultrasound examination is because it has no radiation adverse effects; therefore, it is considered as a safe technique for all patients. Transthoracic ultrasonography could evaluate abnormalities in the peripheral lung parenchyma, pleura and chest wall. Visualization of lung parenchyma and pleura is performed by scanning along the rib interspaces during normal respiration and breath-hold respiration to evaluate greater details of lesions. Thoracic ultrasonography may also be utilized as guidance in performing invasive procedures, such as pleural puncture, transthoracic biopsy and chest tube insertion.<sup>1,2</sup>

## BASIC PRINCIPLES

In order to perform a good examination and appropriate interpretation of the examination results, basic principles of ultrasound should be well-understood. Like any other imaging modalities, clinical data of the patient such as medical history, physical examination and laboratory results are required prior to the examination

Other imaging results such as chest radiography, which is generally provided by previous evaluation and if there is any other radiographic result such as thoracic CT scan, all of them should be evaluated first. Furthermore, recognizing ultrasound equipment and obtaining basic principles about how it works are also required in order to perform proper examination. There are some points that should be noticed by the examiner regarding the ultrasound equipment, i.e. the type of transducer, preset and frequently-used terminology, the echogenicity.<sup>1,2</sup>

### Echogenicity

Echogenicity is a term used to assess the image, which appears on the screen and is expressed in the form of gray scale (echogenicity scale). A structure with strong echo density will appear white; while those with weak echo density, that no sound wave will be reflected, will appear black.

Echogenicity image obtained on lung sonographic examination is determined by the amplitude of reflected or echoed wave amplitude. Anechoic image will be obtained when there is no reflected sound wave, so that the image will appear in the form of black shadows, for example in pleural effusions. When the echo waveform obtained is comparable to the surrounding tissue, the isoechoic densities will appear, such as the kidneys and spleen. When the density of the obtained echo is stronger than the surrounding tissue, such as the density obtained from the diaphragm; then the image will appear in the form of a white shadow and called hyperechoic. In contrast, it will be called hypoechoic when the density is lower than the surrounding tissue, which result in darker image.<sup>1-3</sup>

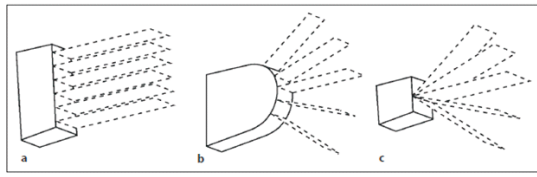
### Transducer Type

To get a better quality of image, the power of ultrasound should be set/ adjusted, which leads to adequate echo density. Along with the increased of wave frequency, the penetration of sonographic wave into the tissue is reduced.

Superficial organs will be better visualized by using a transducer with higher frequency; in contrast, it would be better to use a transducer with a lower frequency for deeper structure.

Most of the ultrasound devices are equipped with a special mode for specific organs, which may provide a better image results. For a superficial structure examination, the thyroid gland preset is used; while for the examination of the chest cavity structure, we use the abdominal preset.<sup>1</sup>

The selection of transducer sizes is very essential in real-time ultrasonography examination. There are three types of transducer that can be used, such as linear array, curvilinear array and phased array (**Figure 1**). Linear array transducer forms parallel pulse shape which provides a rectangular image. Linear array transducer with 7.5 to 10 MHz frequency is used for sonographic examination of superficial structures; such as to recognize the presence of pleural thickening, pleural masses and subpleural lung parenchyma lesions. The convex surface of curved array transducer will form a radial pulse producing widespread area of visualization. This type of transducer is excellent for showing the existence of a massive pleural effusion and for lung examination through abdominal approach.



**Figure 1.** Various types of the ultrasound transducers (a. Linear array transducer, b. Curvilinear transducer, c. Phased array transducer)

Phased array transducers with 2 -5 MHz frequency are used for examination of deeper structures, for example to evaluate the presence of pulmonary atelectasis and complicated pleural effusion.<sup>1,2</sup>

The popular term that is often used in lung ultrasound examination is the earth-sky axis. Organs in the chest cavity are mainly composed of water and air. In accordance with the law of gravity, air will always be on top while liquid will always be under, then moving according to the patient's position. It is necessary to understand the patient anatomy of various organs in the body cavity in various positions in order to obtain good examination results. Presence of enlarged lymph nodes or tumor in the anterior mediastinal cavity that does not pertain to chest wall in the supine position, should be examined in the right or left lateral decubitus position and slightly pronated; thus, it allows existing abnormalities to be nearer to the chest wall.

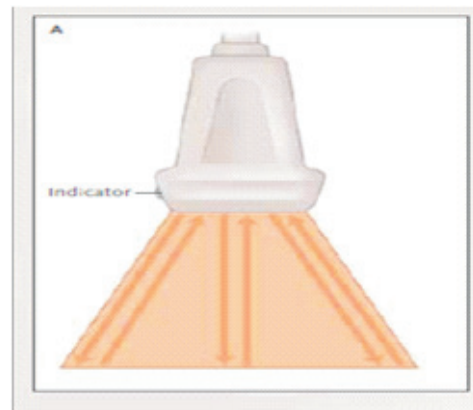
The pleural cavity can be better visualized by placing the transducer at the posterior wall and the patient in a sitting position with a sore arm is placed on the contra lateral shoulder or on the head. To detect a minimal pleural effusion, patients should be examined in an upright sitting position so that fluid will accumulate in the costo-diaphragmatic recess. To detect pleural effusion fluid in a patient in supine position, the transducer must be placed parallel close to the patient's bed.<sup>1,2,4</sup>

### Transducer Orientation

In order to interpret the results properly, the obtained sonographic examination data should always be associated with the anatomy of various organs in the chest cavity and also clinical data of the patient. Although ultrasound examination of the lungs provides a two-dimensional images, by observing respiratory movement intensively when sliding the transducer then shadow can be obtained as if it is a dynamic

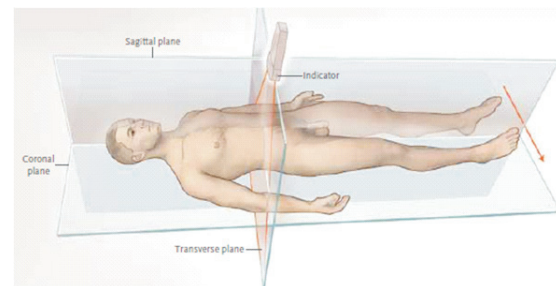
3-dimensional. The ability to see the pathological abnormalities in three dimensions is important in interpreting the results of the examination. To determine the position of the transducer, some points should be considered including clinical complaints, abnormalities obtained from physical examination, chest X-ray and CT-Scan (if available), as well as mobilization ability of the patient. For all above points, the experience of doctor who will perform examination is needed.<sup>1</sup>

Each transducer is equipped with a probe indicator that will determine the direction of the examination and related to the marker, which is associated with a marker of the display screen (**Figure 2**). Generally, the marker will appear at the top left corner on the display screen.



**Figure 2.** Transducer equipped with probe indicator

To perform examination on a sagittal section, a probe indicator transducer is placed in cephalad direction position. During the examination, probe indicator is placed in the cranial direction to the possible maximum extent through the intercostals window along the axis of the ribs. For examination in the transverse plane, the probe indicator is directed to the right side of the patient (**Figure 3**).<sup>3</sup>



**Figure 3.** The probe transducer location and the indicator direction in various planes

Structures within the chest cavity could be better visualized by retaining the transducer location along the longitudinal (sagittal) axis or transverse ribs on the sidelines. Sometimes it takes repeated attempts to get the best position and angle of view when the inspection target of a particular structure is conducted. Anatomic landmarks can help the investigation, especially when performing invasive procedures. Pleural surface on the right side is limited by the diaphragm and the liver, while the left side is by the diaphragm and the spleen.

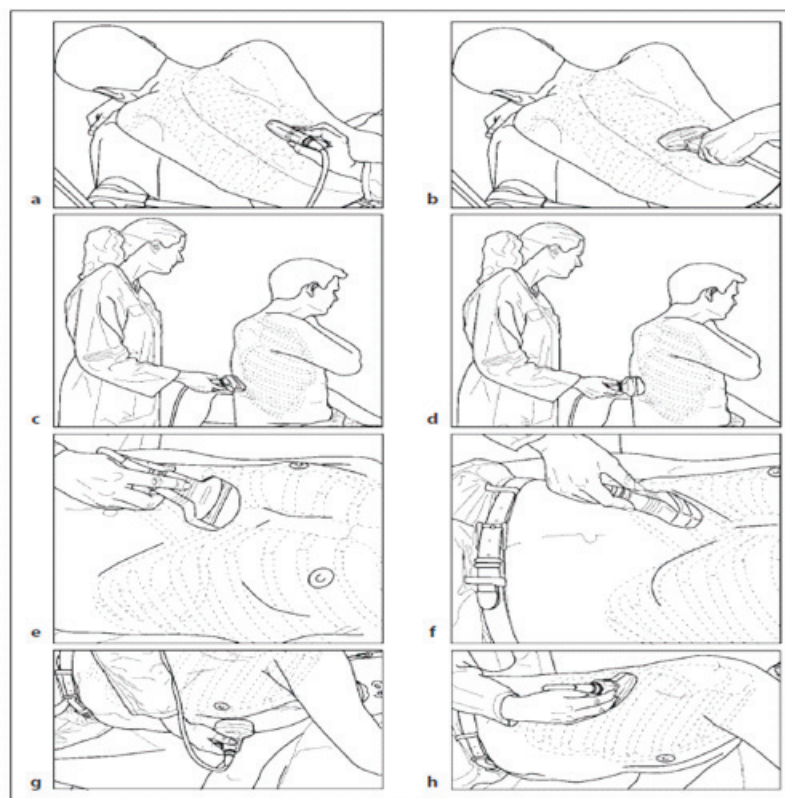
### EXAMINATION TECHNIQUE

In order to do a comprehensive examination, the examiner, the patient and the transducer position is arranged in such a flexible manner. Transducer can be placed at several location along the chest wall, it depends on the abnormalities for location being examined (**Figure 4**). To examine abnormalities on the chest wall and the posterior pleural cavity, the patient is in the decubitus lateral position and the transducer is placed on the sidelines of the ribs longitudinally with the probe indicator leads to the cranial (a). The transducer can also be placed transversely, with the probe

leading to the right side of the patient (b). For examination of the chest wall and posterolateral pleural cavity of the patient in a sitting position, the transducer is placed longitudinally with the probe indicator leads to the cranial (c). The transducer is placed transversely with the probe indicator leads to the right side of the patient (d). For cardiac examinations, xiphisternal approach is performed with the probe indicator leads to the right (e), transhepatic approach taken to assess the pleura, diaphragm and liver in a patient in a supine position (f). Examination of the mediastinum is performed in the left lateral decubitus position and slightly pronated so that the mediastinal structures is getting closer to the anterior chest wall (g) and thus also for the lateral chest wall examination, the patient position is in the left lateral decubitus (h).<sup>1,4</sup>

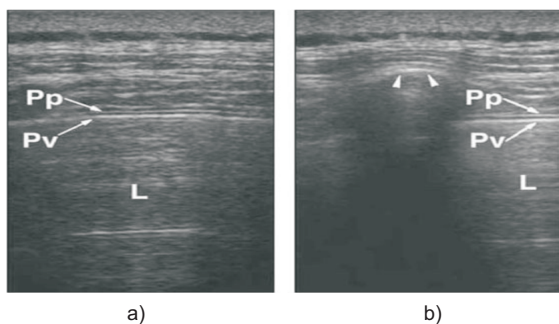
### NORMAL THORACIC ULTRASOUND IMAGES

By using low-frequency transducer (3.5 MHz) on the normal chest wall, echogenic image showed connective tissue layers which composed of muscles and fascia. On sagittal (longitudinal) cuts of rib-cage will appear in the form of a curved structure with posterior acoustic



**Figure 4.** The various patient position and transducer location on thoracic ultrasound examination

shadowing, while the transverse anterior cortex cut of the ribs will appear in the form of smooth echogenic lines at the bottom of the connective tissue. The parietal and visceral pleura appear in the form of a high level echogenic line under the ribs that describes the pleural surface. By using a linear transducer that has a high resolution, the two pleural layers will be seen as two lines with different echogenic, where the parietal pleura may appear thinner (**Figure 5**). The layers of the pleura appear to move each one to the other during inspiration and expiration. With real-time imaging would seem that the movement of pleural layers, known as gliding sign. Further pulmonary respiratory movement against the chest wall known as the lung sliding sign.<sup>1-3</sup>

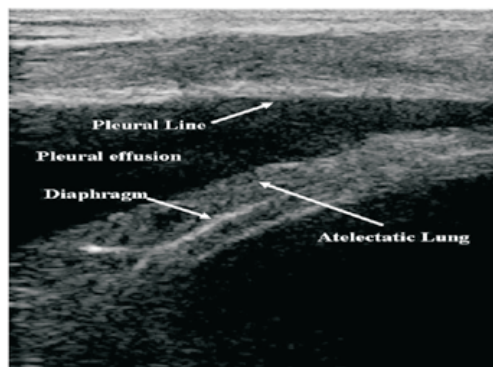


**Figure 5.** Normal thoracic ultrasound image display in the transverse plane (a) and sagittal (b) Pp: Parietal pleura, Pv: Visceral pleura, L: Lung

### Pleural Effusion

The pleural effusion ultrasound examination is useful to analyze the possible types of localized or diffuse pleural effusion. To detect the presence of minimal pleural effusion, ultrasound examination is more sensitive than the lateral decubitus position image examination. In addition, to detect the presence of effusion, ultrasound can also be used to estimate the amount of pleural fluid. In sonography, pleural effusion will appear in the form of a homogeneous anechoic shadow between the parietal pleura and visceral pleura (echo-free zone separating the visceral and parietal pleura) (**Figure 6**). This shadow can change its shape due to respiratory movement (echo-free zone, displaying a change during breathing), and lung in the pleural fluid will experience a collapse (atelectasis) that appear in the form of a structure that resembles a tongue (tongue-like structure). Another sonographic image from the pleural effusion is the presence of echogenic particles

that move/hover, shadows of a moving septa and lung tissues that move in the liquid. The effusion caused by inflammation induced an adhesion between two layers of pleura, which leads to an inhibition of lungs movement.<sup>1</sup>



**Figure 6.** Pleural effusions ultrasound image

When the chest images obtained abnormal elevation of hemi diaphragm, the ultrasound examination can distinguished whether the abnormality is due to subpulmonic pleural effusion, or diaphragm paralysis due to fluid accumulation under the diaphragm. Image obtained on sonographic effusion is influenced by several factors: the nature of disease, the cause of effusion and the chronicity of the disease. There are 4 displays that can be obtained by internal echogenicity sonography, such as (a) anechoic, (b) complex non-septated, (c) complex septated, and (d) homogeneously echoic (**Figure 7**). Generally, the transudates pleural fluid is anechoic, unseptated and free flowing, whereas the complex, septated, or echogenic is generally exudative. The malignant pleural effusion is often anechoic and sometimes a nodular pleural thickening and echogenic swirling are found. In the pleural effusion due to inflammatory, the strands of echogenic material and septation, that come to move in accordance with the breathing rhythm and the heart contraction, are found.<sup>1,4-7</sup>

In practical terms, the pleural fluid volume can be estimated based on the 4 classifications, such as minimal (limited echo-free space in the costophrenic angle), small (echo-free space exceeds the costophrenic angle but still confined to the area covered by a 3.5 MHz curvilinear transducer), moderate (echo-free space exceeds one transducer but still within two-probe range) and large if obtained space is more than two-probe range. Sometimes it is difficult to

distinguish between minimal pleural effusions with pleural thickening because both can show hypoechoic shadow. As a guideline, if mobilities found then this is an important sign for effusion. So the presence of lesions that change shape according to the respiratory and strand image, also moving echo density showed an effusion of pleura.<sup>1,4-5</sup>

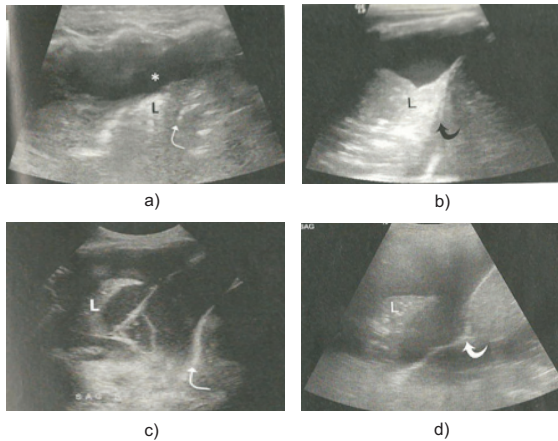


Figure 7. Pleural effusion with 4 types of display image

**Thickening of The Pleura**

Solid lesions in the pleura can result from various etiologies; and the obtained sonographic image can be diffuse (diffuse pleural thickening due to fibro thorax (pleural peel), focal (focal pleural thickening) due to inflammation or fibrosis (pleural plaques) and can also be an image of mass in the pleura which may be caused by a benign tumor, and metastases in pleural mesothelioma.

Diffuse pleural thickening. Diffuse pleural thickening can occur due to fibrosis or pleural effusion due to malignancy which involves the visceral pleura causing trapped lung (entrapped lung) so thus resulted in restriction of ventilation. The most common cause is the result of complicated parapneumonic effusion, empyema and hemothorax. Sonographic results may show varied fibrosis pleural echogenicities, generally hypoechoic, but echogenicities can also look stronger (Figure 8).<sup>1,4</sup>

Localized (focal) pleural thickening. Pleural plaque caused by a localized pleural thickening in sonography will appear in the form of smooth pleural tissue which is causing lung displacement from the chest wall, pleural thickening was evidently limiting normal lung tissue without infiltrating the chest wall (Figure 9).<sup>4</sup>

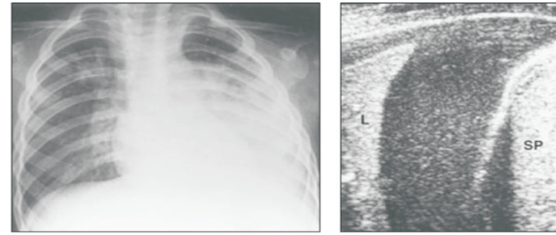


Figure 8. Ultrasound image of the complicated parapneumonic effusion

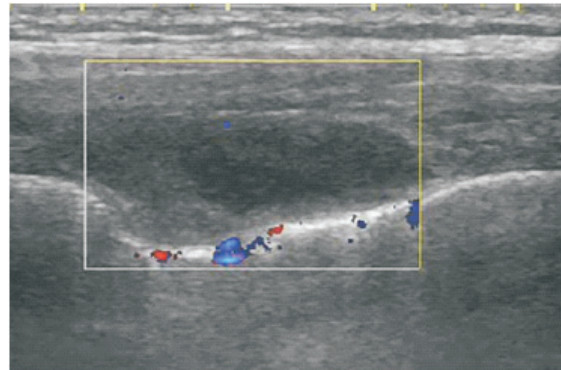


Figure 9. Pleural plaque thickening caused by the visceral pleura presence

Pleural tumors. Benign pleural tumors are very rare and sonographic appears to be demarcated mass with varying echogenicities (depending on fat content) in the parietal or visceral pleura. Tumor metastasis to the pleura will give a nodular polypoid pleural or irregular sheet-like pleural thickening, and often accompanied by massive pleural effusion (Figure 10).

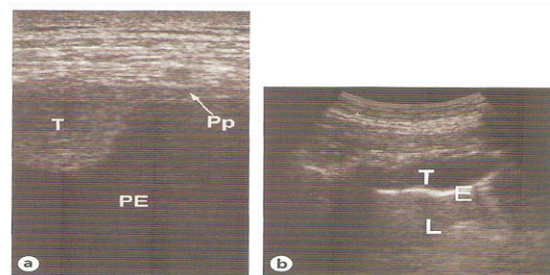
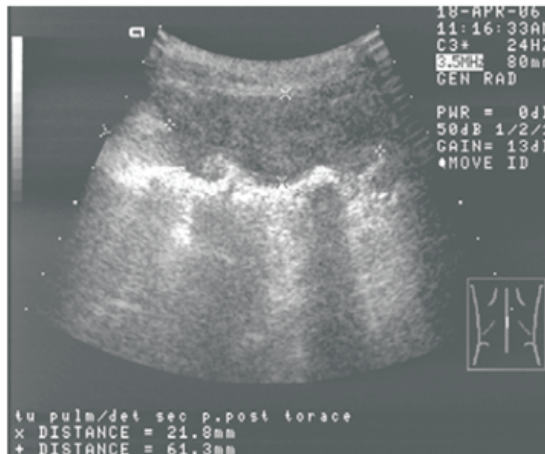


Figure 10. Pleural tumors with polypoid pleural nodules image (a) and irregular pleural thickening (b). Pp: parietal pleura, T: Tumor, PE: pleural effusion.

Pleural mesothelioma is primary pleural tumors that are rarely found but are fatal, usually associated with a history of exposure to asbestos. Sonographic image of mesothelioma is characterized by a diffuse pleural thickening, often nodular and irregular nature, and may be

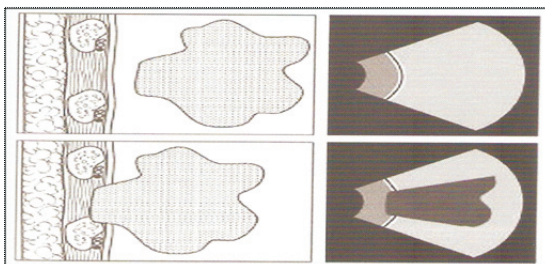
accompanied by pleural calcifications, pleural effusion, and focal pleural mass (**Figure 11**). Mesothelioma is aggressive, so would invade the chest wall, lung parenchyma and diaphragm, also can spread to the pericardium and contra lateral pleura.<sup>1,4</sup>



**Figure 11.** Pleural thickening in mesothelioma

**Lung Tumors**

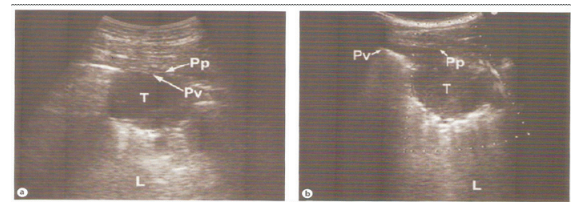
Peripheral lung tumors can be detected by ultrasound as long as the tumor is attached to the pleura (**Figure 12**). These tumors often appear hypoechoic with posterior acoustic enhancement accompanied by parenchymal lung atelectasis that provides a fluid bronchograms.<sup>1</sup>



**Figure 12.** Peripheral lung tumors detached to the pleura (top), not detected by ultrasound, and the tumor attached to the pleura (bottom) that can be detected by ultrasound

The presence of lung tumor invasion into the visceral pleura and chest wall has a significant impact on disease staging. Although routine CT-scan examination has been performed to determine the stage of lung tumors, real-time high-resolution ultrasound examination has proven superior to the CT-scan. All layers of the chest wall (muscle, fascia, parietal and visceral pleura) can be seen with ultrasound, so if there is peripheral lung tumor attached to the chest

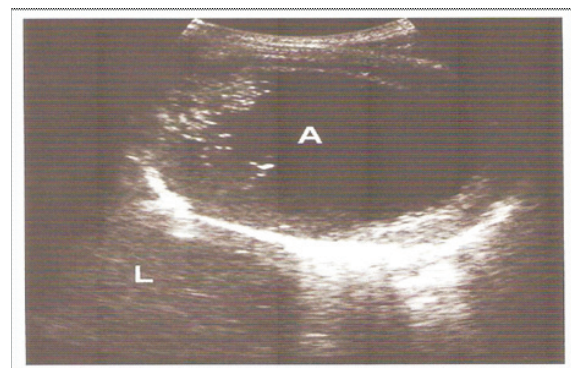
wall then the extent of tumor invasion can be determined more accurately. If the tumor is immobile at the time of respiration it means that the tumor has spread beyond the parietal pleura (**Figure 13**).<sup>1</sup>



**Figure 13.** A peripheral lung tumor that have not been extended to the parietal pleura (a) and which has been extended until it reaches the parietal pleura (b). Pp: parietal pleura, Vp: visceral pleura, T: Tumor.

**Lung Abscess**

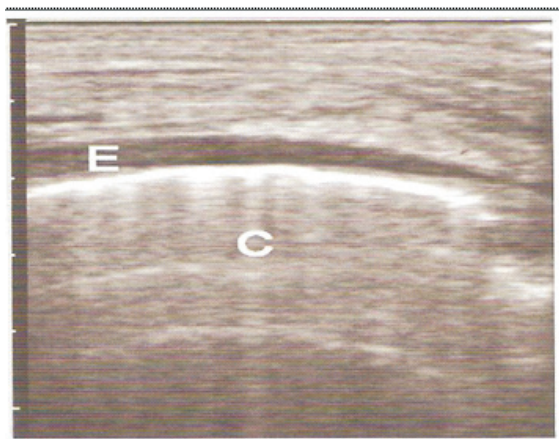
Lung abscess adjacent to the pleura will appear as a hypoechoic lesion in which the boundary wall can be assertive or irregular. The central part of abscesses often appears anechoic, but can also be showed as internal echoes septation (**Figure 14**). Lung abscess with air-fluid levels would reveal more inhomogen.<sup>1</sup>



**Figure 14.** Lung abscess with hypoechoic center image and irregular walls. A: Abscess, L: Lung.

**Pulmonary Edema, Alveolar-interstitial Syndrome and Others**

In patients with acute shortness of breath complaints where lung ultrasound obtained a comet-tail artifact bilateral and diffuse image, it is very likely the cause of shortness of breath is because of pulmonary edema or other alveolar-interstitial syndromes. The comet-tail artifact rarely found in patients with COPD patients, but can be obtained in 93% of patients with alveolar-interstitial syndromes (**Figure 15**).<sup>1</sup>



**Figure 15.** Pulmonary edema marked by the comet-tail artifact image on ultrasound. E: effusion, C: Comet-tail artifact.

### The Role of Ultrasound in The Invasive Pulmonary Procedures

Ultrasonography is very useful in guiding invasive pulmonary procedures, especially for lesions on the chest wall, pleura and peripheral lung. Invasive procedures are often performed in pleural puncture for diagnosis purposes, chest tube installation, pleural biopsy and superficial lung tumors biopsy. The use of ultrasound will increase the success of the procedures and minimize side effects. For the invasive procedural purposes, the reusable probes to guide biopsy procedure are available. However, many experienced clinicians prefer the freehand technique in performing invasive procedures.<sup>1,2,4,8</sup>

Several invasive procedures that can be performed with ultrasound guidance is a chest wall biopsy, pleural fluid aspiration, chest tube insertion, closed pleural biopsy, transthoracic needle aspiration (TTNA) and transthoracic biopsies (TTB).

**Chest wall biopsy.** Fine needle aspiration (FNA) can be performed on soft tissue mass of unknown cause with the help of ultrasound. Sonography can also be used to detect the presence of lung tumor invasion to the chest wall. High-resolution sonography is more superior than routine CT –scan examinations in evaluating the tumor invasion to the pleura and chest wall.<sup>1,2,4,5</sup>

**Pleural fluid aspiration.** Ultrasonography is superior to the chest image examination to determine the location of pleural fluid aspiration. By the help of ultrasonography, the most optimal location can be determined and aspirations will be easily done with a freehand technique. The patient is placed in the best position in

this procedure. Sonographic examination was performed to determine the safest and appropriate insertion location, then it is marked. It is important that the patient's position should not change so that the locations of the marked skin do not move, so it does not fit anymore with the lesion location in the pleura/lung. Sometimes patients need to be asked to hold their breath a few seconds during aspiration. In patients with minimal pleural effusion, the pleural puncture must be performed at bedside position (direct pleural puncture performed immediately after the location specified). The success rate of pleural fluid aspiration with ultrasound guidance reached 97% and the risk of further complications was minimal.<sup>1,2,4,5,9,10</sup>

**Chest tube insertion.** Ultrasonography is useful for determining the safest and effective location for pleural drainage, especially in patients with loculated parapneumonic effusion. In such patients, the pleural thickening, adhesion and loculation often complicated the chest tube insertion. Furthermore, ultrasound is also useful to decide whether or not the further action such as intrapleural fibrinolytic administration, thoracoscopy or surgery.<sup>1,2,4,5</sup>

**Pleural biopsy.** Ultrasonography is also very useful for guiding pleural biopsy procedure. By ultrasound, the identification of focal pleural abnormalities can be performed and the amount of pleural fluid can be estimated, so that the risk of laceration of the visceral pleura can be reduced. Closed pleural biopsy is conventionally performed using Abram needles, it is performed when chest images showed quite lot of effusion fluid. Pleural biopsy with ultrasound guidance can be performed even if effusion fluid is minimal.<sup>1,4,5</sup>

Transthoracic Needle Aspiration (TTNA) and Transthoracic biopsies (TTB). TTNA and TTB procedures, which were performed with the ultrasound guidance to diagnose lung tumor, are considered as a quite safe procedure and with a quite high diagnostic success rate. This procedure is mainly performed on peripheral lung tumors that adjacent or invaded the pleura and chest wall and also on mediastinum tumor, especially tumors in the anterior superior mediastinum. In peripheral lung tumors, biopsy can be performed without penetration to the lung tissue, so that the pneumothorax risk is minimal.<sup>1,4,5</sup> Invasive procedures can also be



performed in immobilized ICU patients due to advanced disease. The diagnostic success rate was 82% and 85.5% for TTNA and TTB, respectively. Pneumothorax complication in TTNA and TTB was relatively low, 1.3% and 4%, respectively. Furthermore, ultrasound can also be used to determine the presence or absence of pneumothorax complication of post procedures. If in post procedures, the tumor lesions still visible and no change either in the location, shape or size meaning no pneumothorax.<sup>1</sup>

### LUNG ULTRASOUND EXAMINATION LIMITATION

Although shown to provide significant advances in treating patients, ultrasound also has some limitations. Even though it can also be used to detect abnormalities in the mediastinum, the benefits are very limited (only for abnormalities in the anterior superior mediastinum) and the quality of sonography results is also highly variable. The ultrasound examination results may not be able to provide an acquired abnormality condition overview globally. Ultrasound examination also cannot be used to determine the location of devices (e.g., endotracheal tube, central venous catheter, NGT) in the chest cavity properly. The ribs structure can inhibit the penetration of ultrasonic waves, as well as a lot of the obtained air in the lungs will reflect the ultrasonic waves. Ultrasound is sometimes difficult in patients with subcutaneous emphysema, anasarca edema and obesity.

Because of the lung ultrasound is often performed at bedside, the matter of infection prevention should become a particular concern. Portable machines must be placed on a special table and should not be placed on the patient's bed. During invasive procedure, the sterility standard procedure should always be carried out. Jelly which is used for the examination could be the germs growth medium, then it should always be cleaned from the body of the patient after examination. Ultrasound device must also be cleaned after each examination to prevent possible transmission of nosocomial infections through the components of the device (transducer, cable and keyboard).<sup>1,2</sup>

### CONCLUSION

Lungs ultrasound examination has a very important role in the treatment of patients with pulmonary and pleural disease. The advantages of ultrasound examination are: it does not result in radiation effects, practical and can detect abnormalities of the pleura/lungs more quickly. The use of ultrasound in pulmonology is very helpful in guiding a variety of invasive procedures that can improve the success rate in diagnosing and treating patients and reducing complications. Its limitations include the lack of use for the mediastinum abnormalities, and the results are operator-dependent.<sup>1,2</sup>

### REFERENCES

1. Islam S, Tonn H. Thoracic ultrasound overview. In: Bolliger CT, Herth FJF, Mayo PH, Miyazawa T, Beamis JF, eds. *Clinical Chest Ultrasound*. Sidney: Karger; 2009. p. 11-20.
2. Anantham D, Ernst A. Ultrasonography. In: Mason RJ, Broaddus VC, Martin TR, King TE, Schraufnagel DE, Murray JF, Nadel JA, eds. *Textbook of Respiratory Medicine*. Philadelphia: Saunders Elsevier; 2010. p. 445-60.
3. Moore CL, Copel JA. Point-of-care ultrasonography. *N Engl J Med*. 2011;364:749-57.
4. Mathis G, Z Sparchez, Volpicelli G. Chest sonography. In: Dietrich CF, ed. *EFSUMB - European Course Book*. Italy: EFSUMB; 2010. p. 2-21.
5. Havelock T, Teoh R, Laws D, Gleeson F. Pleural procedures and thoracic ultrasound: British thoracic society guidelines pleural diseases 2010. *Thorax*. 2010; 65: ii72-ii4.
6. Heffner JE, Klein JS, Hampson C. Diagnostic utility and clinical application of imaging for pleural space infections. *Chest*. 2010;137:467-9.
7. Fraser RS, Colman N, Muller N, Pare PD. *Method of radiologic investigation. Synopsis of Diseases of the Chest*. Philadelphia: Saunders Elsevier; 2005. p. 97-109.
8. Hansell DM, Lynch DA, Mc Adam HP, Bankier AA. Pleura and pleural disorders. *Imaging of diseases of the chest*. China: Mosby Elsevier; 2010. p. 1003-17.
9. Diacon AH, Theron JH, Bolliger CT. Transthoracic ultrasound for the pulmonologist. *Curr Opin Pulm Med*. 2005;11:307-12.
10. Feller D, Kopman. Ultrasound-guided thoracentesis. *Chest*. 2006;129:1709-14.