

Adrenal Incidentaloma

Fenny Elvina Ridho, Fabiola MS Adam, John M.F.Adam

*Diabetes and Lipid Center, Department of Internal Medicine, Faculty of Medicine, University of Hasanuddin,
Jl. Perintis Kemerdekaan, Makasar, Sulawesi, Indonesia.*

Correspondence mail to: johna@indosat.net.id

ABSTRACT

Adrenal Incidentaloma is an adrenal tumor, which is unidentified before the imaging procedures conducted for an abnormality which is initially unforeseen as an adrenal disease. Symptoms and/or clinical signs of adrenal tumor do not have to be present prior to a diagnosis. Adrenal Incidentaloma can be divided into non-hypersecreting adrenal adenoma, hypersecreting tumor, primary adrenal carcinoma, other adrenal mass, and metastases. The majority of adrenal tumor is non-hypersecreting adrenal adenoma, but it is always considered as hypersecreting tumor until proven otherwise. Some conditions that can be found due to hormonal activity of adrenal incidentaloma is subclinical Cushing's syndrome, pheochromocytoma, aldosteronoma (Conn's disease), and several tumors which secrete androgen and sex hormone. Diagnostic approach of adrenal incidentaloma is focused on two main problems, which are, whether the lesion is hormonally active even though lacking characteristic clinical signs, and whether the lesion is benign or malignant; thus it needs hormonal and radiologic evaluation, even a fine needle biopsy. The management for adrenal incidentaloma includes surgical removal for hormonally active adrenal tumors, or inactive tumors with size less than 4 cm. Monitoring of tumor's hormone level and size are necessary for non-hypersecreting tumor without surgical removal.

Key words: *adrenal incidentaloma, tumor, hypersecreting tumor.*

INTRODUCTION

Adrenal incidentaloma is an adrenal tumor; its existence is unknown and was found incidentally during radiologic examination. A tumor is not classified as adrenal incidentaloma if it is found on imaging studies to look for metastases, or previous suspicion of adrenal abnormalities.¹

Some decades ago, autopsy studies reported adrenal tumor was found on 32% cases; however, in pre-mortal condition, no adrenal tumor was suspected.²⁻⁴ At that time, the tumor was classified as adrenocortical tumor which was asymptomatic and rare.¹ Since the imaging techniques are getting more and more advanced, such as ultrasonography (USG); computerized tomography (CT) scanning and magnetic resonance imaging (MRI), consequently adrenal tumor is easier to be detected; hence, the diagnosis of adrenal incidentaloma is more frequently made and is labeled as "diseases of the modern technology".^{5,6}

The incidence and prevalence of adrenal incidentaloma is unspecified, but on autopsy studies, the incidence of asymptomatic adrenal tumor varies from 1.4%-8.7%. The prevalence of adrenal incidentaloma increases with age, less than 1% in patients below 30 years of age and increases to 7% in patients over 70 years of age. There is no difference in prevalence based on race and sex.^{7,8}

Approximately 80% of adrenal incidentaloma is benign and does not secrete hormone (non-hypersecreting), with size less than 2 cm. Several studies report that adrenal incidentaloma is often found unilaterally, often in right adrenal; however, in 2-10% of cases is found bilaterally. Presenting symptom depends on tumor's location and usually atypical until detected later incidentally through imaging.

On February 2003, the National Institute of Health (NIH) issued a consensus on adrenal incidentaloma, in order to help clinician on evaluating and planning a therapy,

associated with metabolic and cardiovascular complication that might occur.^{5,10} This article will discuss about tumor classification, diagnostic evaluation and the management of adrenal incidentaloma.

THE CLASSIFICATION OF ADRENAL INCIDENTALOMA TUMOR

Even though adrenal incidentaloma is labeled as “diseases of the modern technology”, but actually the classification of adrenal incidentaloma does not differ from the previously established classification of adrenal tumor.¹⁰ Adrenal consists of cortex and medulla. Adrenal cortex produces three essential steroids, which are glucocorticoids, mineralocorticoids, and adrenal androgen. Adrenal medulla secretes catecholamines.¹¹

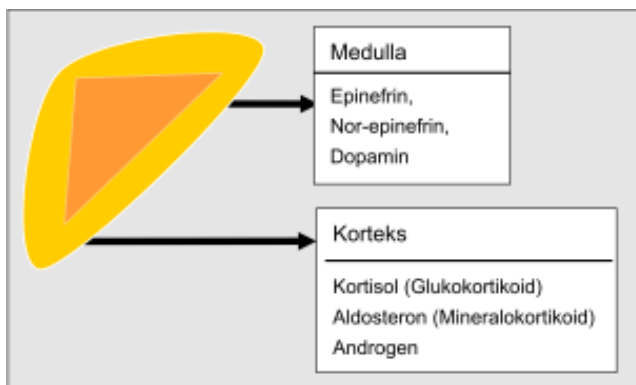


Figure 1. Adrenal and its secreted hormones¹¹

Study Group of the Italian Society of Endocrinology on Adrenal Incidentaloma (AI-SIE) classified adrenal incidentaloma into non-hypersecreting adrenal adenoma, hypersecreting tumor, primary adrenal carcinoma, other adrenal mass and metastases. Mantero et al¹² conducted a study of 1096 cases for 15 years, reported that most of adrenal incidentaloma is non-hypersecreting adrenal adenoma (74%). Hypersecreting tumor is on the second rank (14.8%), followed with other adrenal mass (6.4%), primary adrenal carcinoma (4%) and metastases (less than 1%).^{12,13}

Hypersecreting tumor consists of cortisol secreting adenoma and it manifests as Subclinical Cushing's Syndrome (SCSS), aldosteronomas which are aldosteron-secreting adrenal cortex adenomas manifested as Conn's disease, and pheochromocytoma, which is an adrenal medulla tumor. These three tumors are types of tumor which are closely associated with cardiometabolic risk and requiring proper management. Other type of tumor that should be noticed is primary adrenal carcinoma, because it needs appropriate therapeutic approach.^{11, 14, 15}

Tabel 1. Prevalence of adrenal incidentaloma

	AI (%)
Non-hypersecreting adrenal adenomas	74
Hypersecreting tumors	
Cortisol-secreting adenomas	9.2
Aldosteronomas	1.4
Pheochromocytoma	4.2
Primary adrenal carcinomas	4.0
Other adrenal masses	
Myelolipomas	3.0
Cysts	1.9
Ganglioneuromas	1.5
Metastases	0.7

Data are from the Study Group of the Italian Society of Endocrinology on Adrenal Incidentaloma¹²

The study of AI-SIE also reported that the majority of hypersecreting tumor is cortical tumor, particularly the cortisol secreting adenoma.¹

DIAGNOSTIC APPROACH OF ADRENAL INCIDENTALOMA

The next step subsequent to diagnosis of adrenal incidentaloma is determining the tumor's type by means of further evaluation. The optimal diagnostic approach is still controversial; however, the *National Institute of Health (NIH) state-of-the science conference statement* proposes a diagnostic algorithm to help the clinicians. Most adrenal lesion is benign and hormonally inactive (non-hypersecreting adenoma), thus cost-effective management is important for patient's benefit, by avoiding unnecessary diagnostic intervention.^{2,8,16,17}

Diagnostic approach of adrenal incidentaloma, according to *NIH state-of-the science conference*, intends to determine the type of adrenal tumor and focuses on two main problems, which are, whether the lesion is hormonally active although there are lack of characteristic clinical signs, and how great is the risk of it to be malignant.^{1, 18} These problems can be answered through a meticulous history taking, hormone evaluation and other additional examination as necessary.

Clinical Manifestation

A careful history taking is needed to differentiate whether the tumor is non-hypersecreting, hypersecreting, or others. Approximately 80% of adrenal incidentaloma cases are asymptomatic or atypical, although if it is analyzed retrospectively and thoroughly, symptoms that represent adrenal hormone hyper-secretion are found in some cases. Clinical manifestation as complained depends on the type of hormone being secreted by the tumor. If there is no hormonal imbalance associated symptoms, then the non-hypersecreting tumor may be considered.^{3,19}

The NIH state-of-the science conference suggests that all adrenal incidentaloma should be considered as a hypersecreting tumor, particularly pheochromocytoma, even without clinical manifestation until proven otherwise by ways of hormonal testing. Such consideration should be achieved since the minimal clinical manifestation has demonstrated evidence to have severe complication.^{7,20,21}

1. Hormone Hypersecreting Tumor

- a. **Cortisol Secreting Adenoma.** Cortisol secreting type of adrenal incidentaloma is called Subclinical Cushing's Syndrome (SCSS). Clinical symptom that can be found on SCSS depends on the level of glucocorticoids secreted by the tumor, ranges from small increment of diurnal cortisol rhythm to occurrence of complication. Sub-clinical Cushing's syndrome is used to refer a glucocorticoid hypersecreting tumor which doesn't possess the Cushing's syndrome's stigmata; hence, the diagnosis can only be affirmed by a positive biochemistry assay.²²

Sub-clinical Cushing's syndrome is reported to be closely associated with high cardio-metabolic risk, though without any typical symptoms, since cortisol acts as insulin's counteract, i.e. increases sympathetic activity, vascular tone, hypercoagulability and arterial hypertension.⁵ This has been proven through a study conducted by Rossi et al.²³ reporting that there is a correlation between hypertension, insulin resistance, glucose and lipid metabolic disorders, obesity (cluster metabolic syndrome), and osteoporosis on SCSS subjects. AI-SIE study reported that the prevalence of hypertension is 41% and diabetes is 10% on SCSS subjects.¹² The other study by Tauchmanova et al.²⁴ on 126 SCSS patients also reported that 28 subjects of them had poor cardiovascular and metabolic status.

- b. **Aldosteronoma.** Aldosteronoma or aldosteron secreting adenoma manifests as Conn's disease. The possible clinical manifestation that may be found in AI Conn's disease is mild hypertension. Some literatures state that Conn's disease on adrenal incidentaloma as a subclinical Conn's disease in patients with positive hormonal test but totally asymptomatic.^{25,26}
- c. **Androgen and sex hormone hypersecreting cortical adrenal tumor.** Androgen and sex hormone secreting tumor is very rarely found in adrenal incidentaloma. Generally, it is found as adrenocortical carcinoma. Clinical symptom may

include mild and atypical hyperandrogenism.¹⁴

- d. **Pheochromocytoma.** Study by Sutton et al.²⁷ in 1981 reported that only a quarter of pheochromocytoma cases were detected ante mortem, the remainders were found on post mortem. Most patients die due to cardiovascular complication even before pheochromocytoma was diagnosed. Retrospective analysis shows that 90% of pheochromocytoma patients have a history of hypertension with pathognomonic pheochromocytoma triad, including headache, perspiration, and palpitation, which make it possible to be detected. On the other side, such triad symptoms rarely noticed and it is missed by the clinicians due to its paroxysmal quality and considered as a common discomfort. Approximately 10-40% of pheochromocytoma on adrenal incidentaloma is asymptomatic and it is called sub clinical pheochromocytoma.^{26,28,29}

2. Other adrenal mass and metastases

Other adrenal masses include myelolipoma, cyst and ganglioneuroma; however, they are rare and no typical or characteristic symptom is found. Adrenal is the most common site of metastases. The major sources of metastases are breast, lung, kidney, melanoma and lymphoma. Adrenal metastases, which is incidentally found and diagnosed as adrenal incidentaloma, is generally asymptomatic.^{9,12,26}

Hormonal Testing

Although most of adrenal incidentaloma are non-hypersecreting adenoma; studies on hormonal screening showed 20% of adrenal incidentaloma was asymptomatic hormone hypersecreting tumor. Consensus issued by NIH state-of-the science conference and AI-SIE suggest hormonal screening for every patient with adrenal incidentaloma.^{1,5}

Preliminary hormonal screening, consisting of 24-hour urinary catecholamines and 1 mg dexamethasone suppression test, are performed in patients with diagnosis of adrenal incidentaloma. If the patient has hypertension, then aldosteron/plasma renin activity (PRA) ratio is also tested. A positive result of 24-hour urine catecholamines supports the pheochromocytoma diagnosis, although negative result does not completely rule out pheochromocytoma. A positive 1 mg dexamethasone suppression test supports SCSS diagnosis; while an abnormal aldosteron/plasma renin activity (PRA) ratio supports the diagnosis of Conn's disease. Routine test for sex hormone hypersecretion is not indicated in the literatures due to the small number of prevalence.^{11,17}

Further hormonal evaluation is required to confirm the diagnosis if one of the preliminary hormonal evaluations shows positive result. Further test to establish the diagnosis of pheochromocytoma is the metanephrine/normetanephrine urine test. For SCSS, subsequent corticotropin-releasing hormone (CRF) test or measurement of urinary free cortisol (UFC) level is performed. In addition, NaCl suppression test and measurement of aldosterone plasma level are performed for Conn's disease.^{11,28} When the result of hormonal evaluation is abnormal, hormone non-hypersecreting tumor is considered and followed by re-evaluation of imaging studies to determine the next step.^{1,12,18}

The bigger the size, the greater possibility of tumor actively secretes hormone. Approximately 40% of tumor sized 6 cm in diameter is hypersecreting tumor (figure 2). Tumor with the size less than 2 cm rarely has abnormal hormonal testing, except for aldosterone secreting tumor since although it has small size, this tumor can still cause significant hypertension.¹⁸

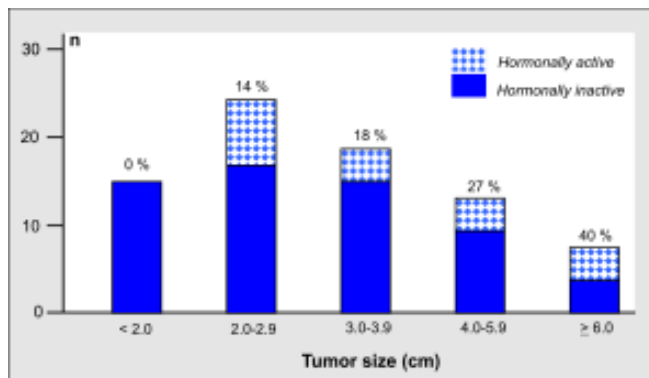


Figure 2. Endocrine activity and tumor's size in adrenal incidentaloma.

Imaging Studies

Once the diagnosis of adrenal incidentaloma has been confirmed and hormonal testing to classify the tumor has been performed, the next step is to re-evaluate the tumor size based on previous imaging study. If the initial imaging study cannot determine the tumor size, then more sensitive imaging study is required. Imaging studies including abdomen CT scan, MRI and adrenal scintigraphy are recommended.^{22, 30}

Of all other radiologic examinations, abdomen CT scan is the best choice since it is considered to be cost-effective. Homogeneous lesion with size less than 4 cm and density less than 15 HU, without enhancement to contrast administration, usually illustrates benign tumor.

On the contrary, inhomogeneous lesion with irregular border and enhancement to contrast administration generally illustrate a malignancy. Tumor metastases shows irregular border, found bilaterally in both glands, with irregular circular enhancement.¹ MRI is regarded as more superior than abdomen CT scan in identifying pheochromocytoma and carcinoma infiltration.^{5,16}

Adrenal scintigraphy is performed on large non-hypersecreting lesion (>3 cm) with inconclusive abdomen CT scan. Adrenal scintigraphy uses iodomethyl-norcholesterol method and ¹³¹I-metaiodobenzyl guanidine (MIBG). ¹³¹I-NP-59 is considered more appropriate for SCSS screening; whereas MIBG is more suggested for sub-clinical/silent pheochromocytoma.^{5,30,31} The latest imaging study is Positron Emission Tomography (PET) which uses ¹⁸F-fluorodeoxyglucose (FDG). The advantage of FDG-PET includes its ability to differentiate primary adrenal tumor from metastases of adrenal tumor by non-invasive technique.^{1,32}

Fine Needle Aspiration (FNA)

Adrenal FNA is not a routine test for adrenal incidentaloma. Cook et al.²² stated that FNA is only used when metastases of the tumor to adrenal gland is suspected. FNA may assist identifying the metastases, but it cannot differentiate an adenoma from primary adrenal carcinoma. A study by Kieven et al.³³ reported that FNA has 91% sensitivity and 97% specificity in identifying metastases.

It is better to perform FNA only when the type of adrenal tumor cannot be determined, neither clinically nor by hormonal testing. The diagnosis of pheochromocytoma must be ruled out prior to FNA, because it may potentially cause hypertensive crisis or sudden death.

MANAGEMENT

The management of adrenal incidentaloma is still controversial. The main problem that needs to ponder prior to deciding therapy plan is the same as diagnostic approach plan, i.e. assessing the characteristics of the tumor, whether it is hormonally active or malignant.^{5,35} Adrenalectomy is the best choice for hormone hypersecreting type of adrenal incidentaloma with typical symptoms in patients with adrenal incidentaloma, especially if the tumor types are Conn's disease and pheochromocytoma. The management of SCSS patient is still controversial. A study reported that several SCSS patients may present with metabolic disorder such as insulin resistance, or even progressing to Cushing's syndrome, hence vigilant observation is needed, and adrenalectomy is performed if necessary.²⁴

The size of adrenal incidentaloma can be a parameter in differentiating benign and malignant tumor, although it is hormonally inactive. The size of tumor is measured by CT scan or MRI. Tumor with size less than 4 cm is generally benign, hence adrenalectomy is not recommended; however, repeated CT scan is needed every 3-6 months on the first year and every year for 3 years period, and hormonal re-evaluation should be performed annually. If hormonal status becomes active or the size of the tumor increases, then adrenalectomy is performed. Malignancy is suspected on tumor with size more than 4 cm or lesion with irregular border. Adrenal scintigraphy and cytological examination can initially be performed to lesion with suspected malignancy, or surgical measure may be directly performed. Arnaldi et al¹ suggested surgical removal on tumor sized more than 4 cm, without initially performing adrenal scintigraphy or cytological examination. Adrenalectomy is performed on patients with negative result of adrenal scintigraphy, thus having significant probability towards malignancy, and on patients with

malignancy signs on cytological examination (figure 3).^{1,2,4}

Adrenalectomy can be performed by methods of laparotomy or laparoscopic. Tumor size and tumor malignancy status determine the surgical method. If the tumor size is less than 10 cm, laparoscopic adrenalectomy can be performed. If the tumor size is more than 10 cm, laparotomy is suggested. The surgical method-of-choice for malignancy is laparotomy.³⁶ Studies demonstrated that laparoscopic adrenalectomy has lower morbidity and mortality rate, ranges from 5-10% and 1-2%.^{18, 34}

CONCLUSION

The prognosis of adrenal incidentaloma depends on the tumor. The majority of adrenal incidentaloma is non-hypersecreting tumor, thus having good prognosis. In general, the size of non-hypersecreting tumor is stable, but around 5-20% of the tumors increase in size, whereas 3-4% may shrink. Approximately 20% of adrenal incidentaloma can develop into hypersecreting tumor in 3-4 years period, particularly tumor with size > 3 cm.¹⁴

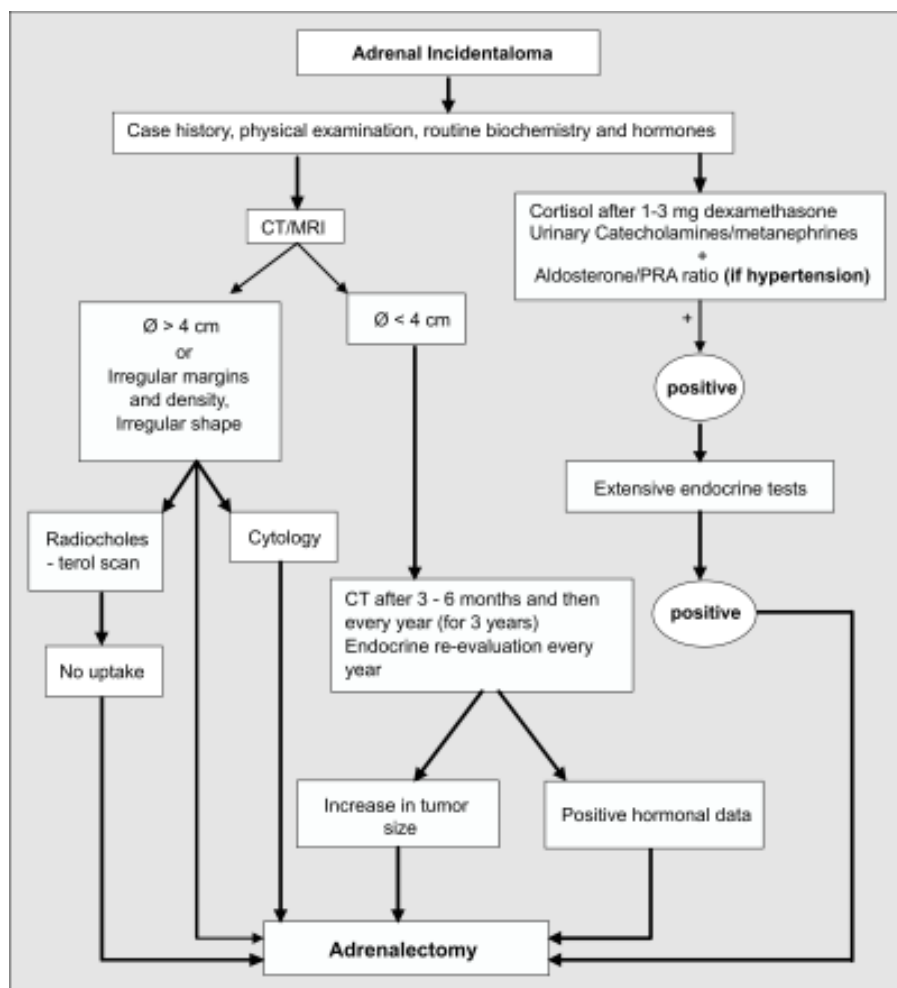


Figure 3. Diagnostic algorithm and management of adrenal incidentaloma¹

Barzon et al³⁷ conducted 2 year-follow up in 75 patients with non-hypersecreting tumor. They reported that 10% of the non-hypersecreting tumor develops into hypersecreting tumor. Other study by Libe et al³⁸ observed 64 patients for approximately 10 years reported that there is a correlation between tumor size increment and transformation of the tumor from non-hypersecreting into hypersecreting type.

The prognosis of hypersecreting tumor will get worse if no surgical measure is taken, because the possible complication due to hypersecreting hormone. Prognosis after surgical removal of hypersecreting tumor is generally good, because the removal can decrease cardiovascular risk such as hypertension, hyperglycemia and hypercholesterolemia.¹⁴ The prognosis of tumor metastases depends on histological profile, staging and location of the primary tumor. Approximately 25% of the tumor with the size > 6 cm is adrenocortical carcinoma with very poor prognosis. A study on adrenal carcinoma reported that the average 5-year survival rate was only 34%.¹⁴

REFERENCES

1. Arnaldi G, Masini AM, Giacchetti G, et al. Adrenal Incidentaloma. *Braz J Med Biol Res.* 2000;33:1177-89.
2. Kloos RT, Gross MD, Francis IR, et al. Incidentally discovered adrenal masses. *Endocrine Rev.* 1995;16:460-84.
3. Mantero F, Arnaldi G. Investigation protocol: Adrenal enlargement. *J Clin Endocrinol.* 1999;50:141-6.
4. Turner HE, Moore NR, Byrne JV, et al. Pituitary, adrenal and thyroid incidentalomas. *Endocrine-Related Cancer.* 1998;5:131-50.
5. Grumbach MM, Biller BMK, Braustein GD, et al. Management of the clinically inapparent adrenal mass ("incidentaloma"). *Ann Intern Med.* 2003;138(5):424-9.
6. NIH Consensus State Sci Statements. 4-6 February 2002;19(2):1-25.
7. Steward PM. The adrenal cortex. In: Larsen PR, Kronenberg HM, Melmed S, et al, eds. *William's Textbook of Endocrinology.* 10th ed. Philadelphia: Saunders; 2003:539-40.
8. Terzolo M, Bovio S, Reimondo G, et al. Subclinical Cushing's syndrome in adrenal incidentalomas. In: Findling JW, Raff H, eds. *Endocrinology and metabolism clinics of North America, Cushing's syndrome.* Vol 34. Philadelphia: Saunders; 2005. p. 423-39.
9. Brunt LM, Moley JF. Adrenal incidentaloma. *World J Surg.* 2001;25:905-13.
10. Angeli A, Terzolo M. Adrenal incidentaloma: A modern disease with old complications. *J Clin Endocrinol Metab.* 2002;87(11):4869-71.
11. Chew SL, Leslie D. Adrenal and endocrine hypertension: Basic concepts. In: Parkinson M, ed. *Clinical endocrinology and diabetes.* London: Elsevier; 2006. p. 22-3.
12. Mantero F, Terzolo M, Arnaldi G, et al. A survey on adrenal incidentaloma in Italy. *J Clin Endocrinol Metab.* 2000;85(2):637-44.
13. Bulow B, Ahren B. Adrenal incidentaloma-experience of a standardized diagnostic programme in the Swedish prospective study. *J Intern Med.* 2002;252:239-46.
14. Nawar R, Aron D. Adrenal incidentaloma-a continuing management dilemma. *Endocrine-Related Cancer.* 2005;12(3):585-98.
15. Ravichandran R, Lafferty F, McGinniss MJ, et al. Adrenal incidentaloma. *J Clin Endocrinol Metab.* 1996;81(5):1776-8.
16. Dwamena BA, Kloos RT, Fenderick AM, et al. Diagnostic evaluation of the adrenal incidentaloma: Decision and cost-effectiveness analysis. *J Nucl Med.* 1998;39:707-12.
17. Terzolo M, Osella G, Ali A, et al. A different pattern of steroid secretion in patient with adrenal incidentaloma. *J Clin Endocrinol Metab.* 1996;81(2):740-4.
18. Slawik M, Martin. Adrenal incidentaloma. In: Chrousos G, ed. *Adrenal physiology and diseases.* 2003. p. 1-17.
19. Mansmann G, Lau J, Balk E, et al. The adrenal mass: Update in diagnosis and management. *Eur J Endocrinol.* 2001;4:151-8.
20. Landsberg L, Young JB. Pheochromocytoma. In: Jameson JL, ed. *Harrison's endocrinology.* New York: McGraw-Hill; 2006. p. 151-8.
21. Franco L, Zucchetta P, Favia G, et al. High risk of malignancy in patients with incidentally discovered adrenal masses: Accuracy of adrenal imaging and image-guided fine-needle aspiration cytology tumor. 2007;93:269-74.
22. Cook DM. The incidental adrenal mass. *Am J Med.* 1996;101:88-94.
23. Rossi R, Tauchmanova L, Luciano A, et al. Subclinical Cushing's syndrome in patients with adrenal incidentaloma: Clinical and biochemical features. *J Clin Endocrinol Metab.* 2000;85(4):1440-8.
24. Tauchmanova L, Rossi R, Biondi B, et al. Patients with subclinical Cushing's syndrome due to adrenal adenoma have increased cardiovascular risk. *J Clin Endocrinol Metab.* 2002;87:4872-8.
25. Barzon L, Fallo F, Sonino N, et al. Development of overt Cushing' syndrome in patient with adrenal incidentaloma. *Eur J Endocrinol.* 2002;146:61-6.
26. Linos DA. Adrenal incidentaloma (adrenoma). *Hormones.* 2003;2(1):456-62.
27. Sutton MG, Sheps S, Lie JT. Prevalence of clinically unsuspected a 50-year autopsy series. *Mayo Clin Proc.* 1981;56:354-60.
28. Ross NS, Aron DC. Hormonal evaluation of the patient with an incidentally discovered adrenal mass. *N Engl J Med.* 1990;323:1401-5.
29. Terzolo M, Ali A, Osella G. Prevalence of adrenal carcinoma among incidentally discovered adrenal masses. A retrospective study from 1989-1994. *Arch Surg.* 1997;132:914-9.
30. Cava GL, Imperiale A, Olianti C, et al. SPECT: Semiquantitative analysis of adrenocortical 131I-6-iodomethyl-norcholesterol uptake to discriminate subclinical and preclinical functioning adrenal incidentaloma. *J Nucl Med.* 2003;44:1057-64.
31. Newel-Price J, Grossman A. Adrenal incidentaloma: Subclinical Cushing's syndrome. *Postgrad Med J.* 1996;72:207-10.
32. Erasmus JJ, Patz EF, McAdams HP, et al. Evaluation of adrenal masses in patients with bronchogenic carcinoma using 18 F-fluorodeoxyglucose-positron emission tomography. *Am J Roentgenol.* 1997;168:1357-60.
33. Kievet J, Haak H. Diagnosis and treatment of adrenal incidentaloma. *Endocrinol Metab Clin North Am.* 2000;29:69-86.
34. Griffing GT. A-I-D-S: The new endocrine epidemic. *J Clin Endocrinol Metab.* 1994;79:1530-1.

35. Herrera MF, Grant CS, van-Heerden JA. Incidentally discovered adrenal tumors: an institutional perspective. *Surgery*. 1991;110:1014-21.
36. Hanks JB. Adrenal gland and adrenal hormones. In: DeGroot LJ, Jameson JL, eds. *Endocrinology*. Vol 2. Philadelphia: Saunders; 2006. p. 2535-46.
37. Barzon L, Scaroni C, Sonino N, et al. Risk factors and long-term follow-up of adrenal incidentaloma. *J Clin Endocrinol Metab*. 1999;84(2):520-6.
38. Libe R, Asta CD, Barbetta L, et al. Long-term follow-up study of patient with adrenal incidentalomas. *Eur J Endocrinol*. 2002;147:489-94.